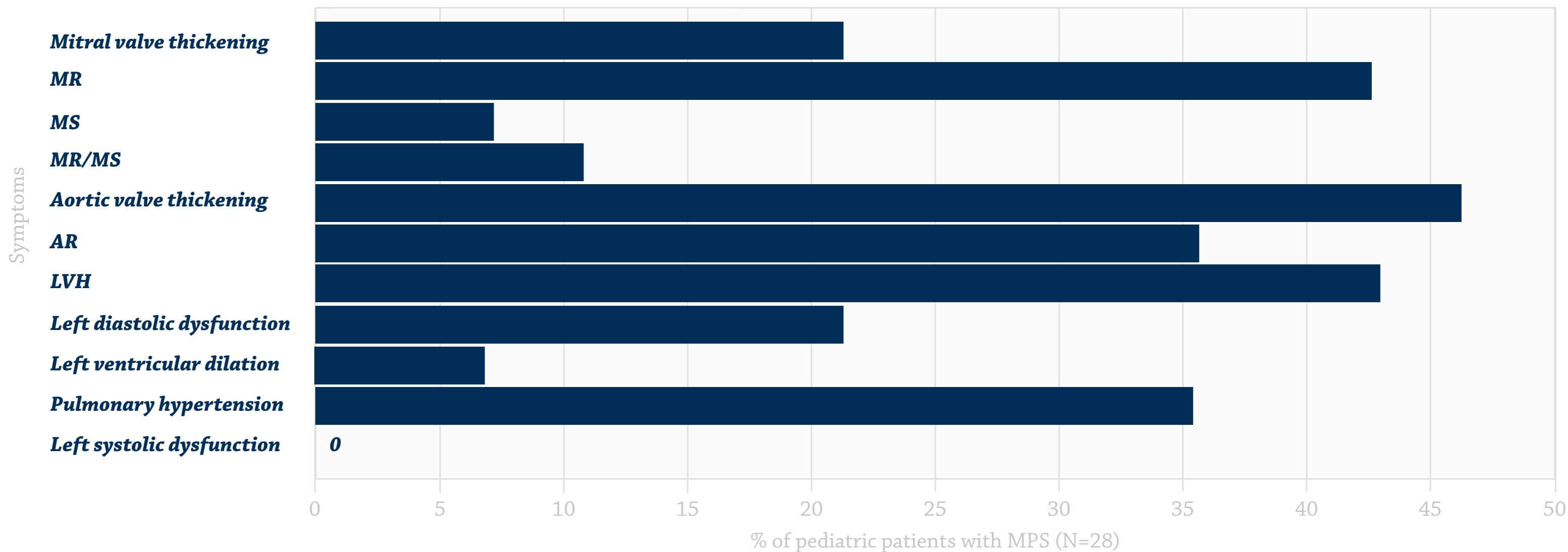


Common cardiac symptoms from echocardiographic evaluation^{1,a}



Adapted from Braunlin, *J Inherited Metab Dis*, 2011.

Abbreviations: AR, aortic regurgitation; LVH, left ventricular hypertrophy, MPS, mucopolysaccharidosis; MR, mitral regurgitation; MS, mitral stenosis; MR/MS, both lesions.

^aEvaluation in 28 patients with MPS I, II, III, IV, VI, and VII ages 2-14 years. The most common cardiac findings in these patients were left valve lesions, left ventricular hypertrophy, and pulmonary hypertension.

Reference: 1. Braunlin EA, Harmatz PR, Scarpa M, et al. Cardiac disease in patients with mucopolysaccharidosis: presentation, diagnosis and management.

J Inher Metab Dis. 2011;34(6):1183-1197. doi:10.1007/s10545-011-9359-8.